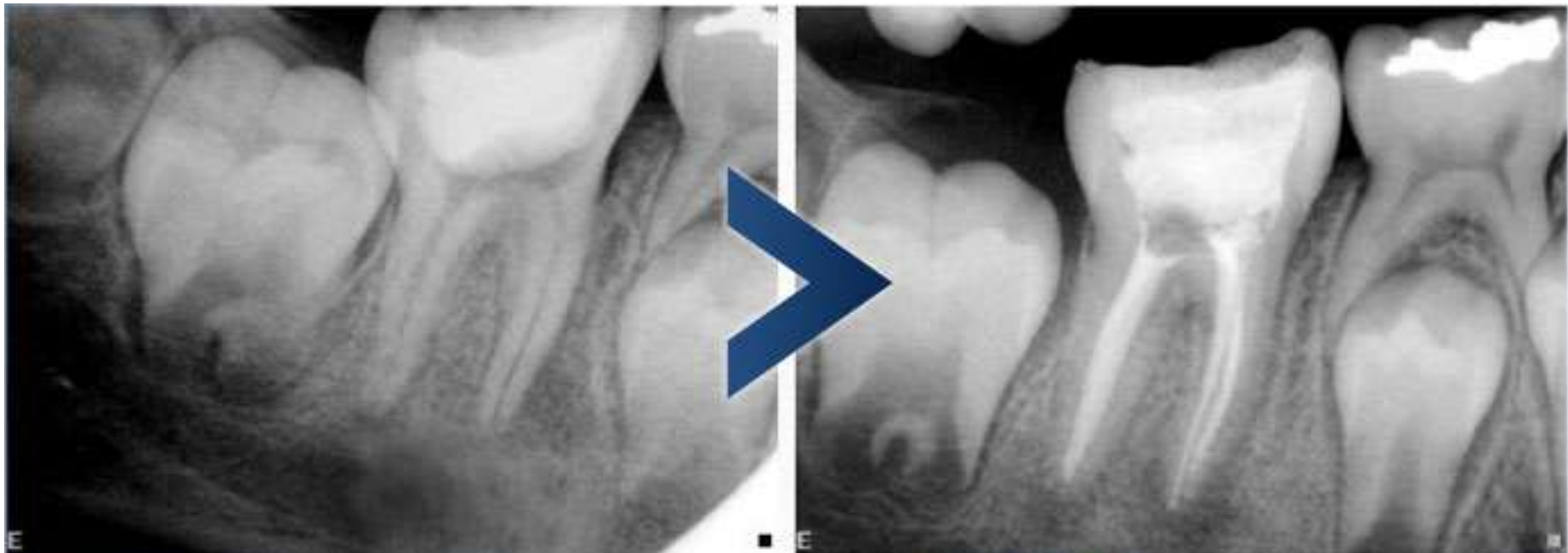


Dra. Chin Patient examples

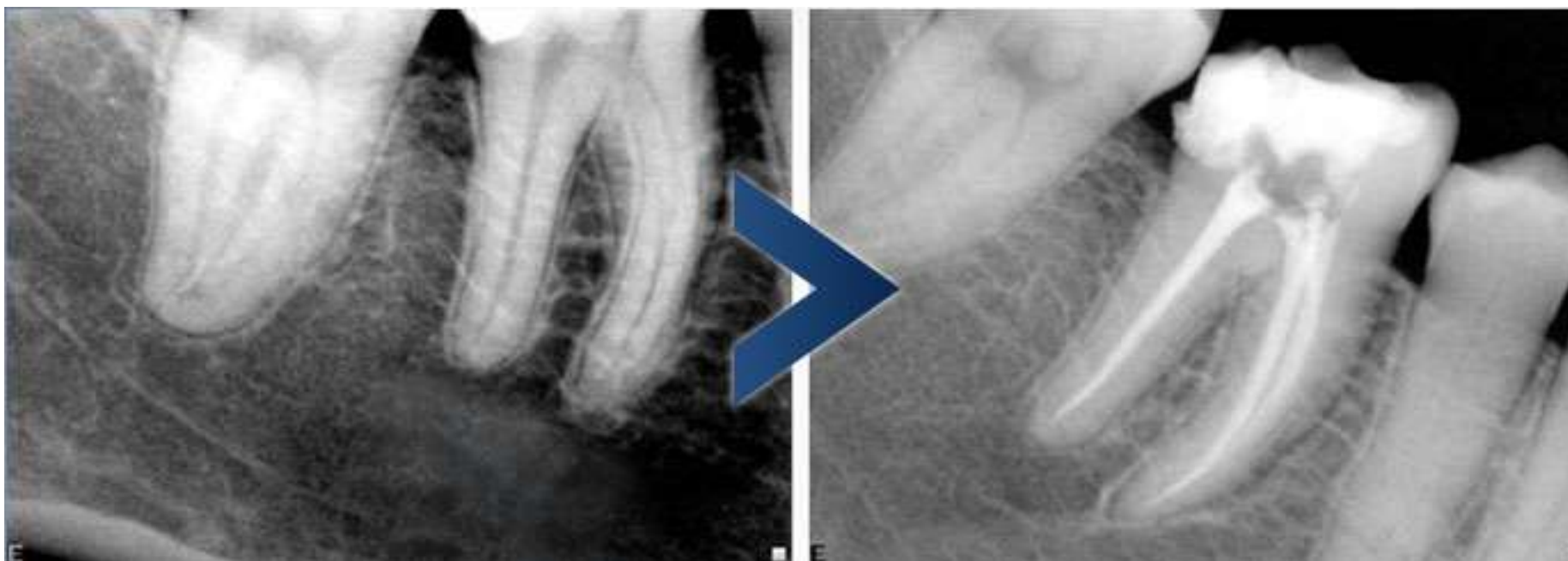Female patient - age: 10

- * Tooth 4.6 with three canals
- * Acute periapical abscess
- * Deep caries required prostodontic and ortodontic evaluation



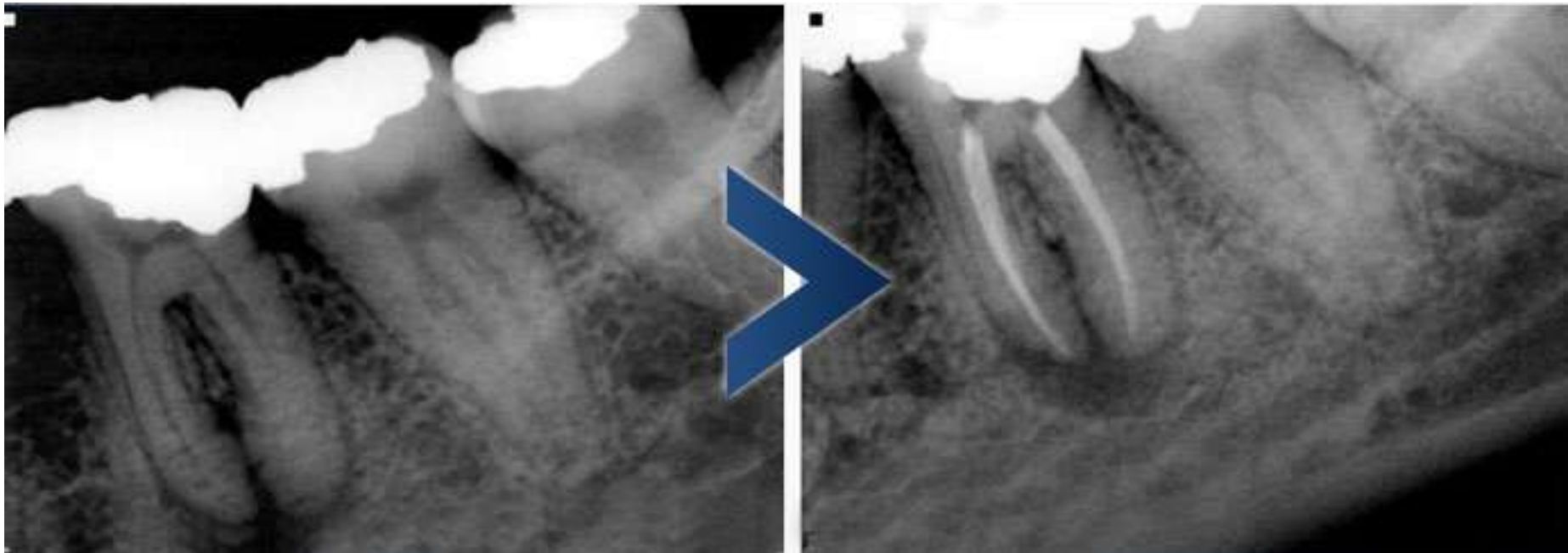
Female patient - age: 22

- * Tooth 4.6 with three canals
- * Irreversible painful pulpitis
- * Deep caries required prostodontic evaluation



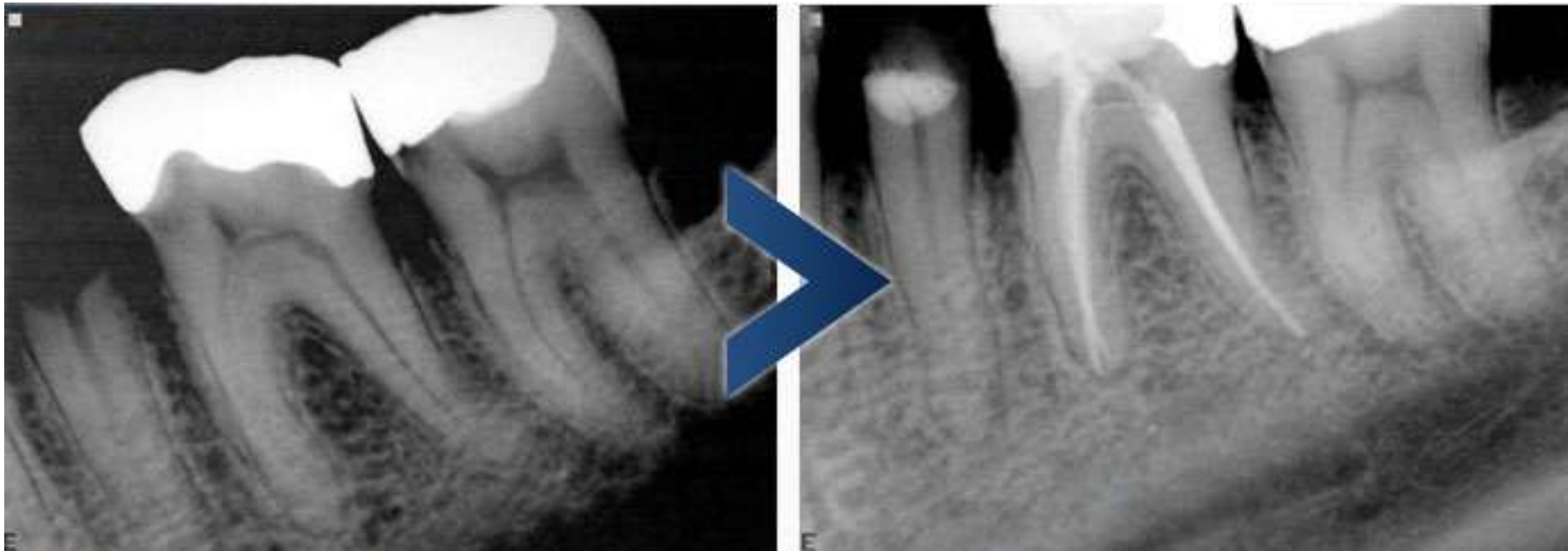Female patient - age: 34

- * Tooth 3.6 with three canals
- * Chronic periapical periodontitis
- * Deep amalgam in contact with distal horn



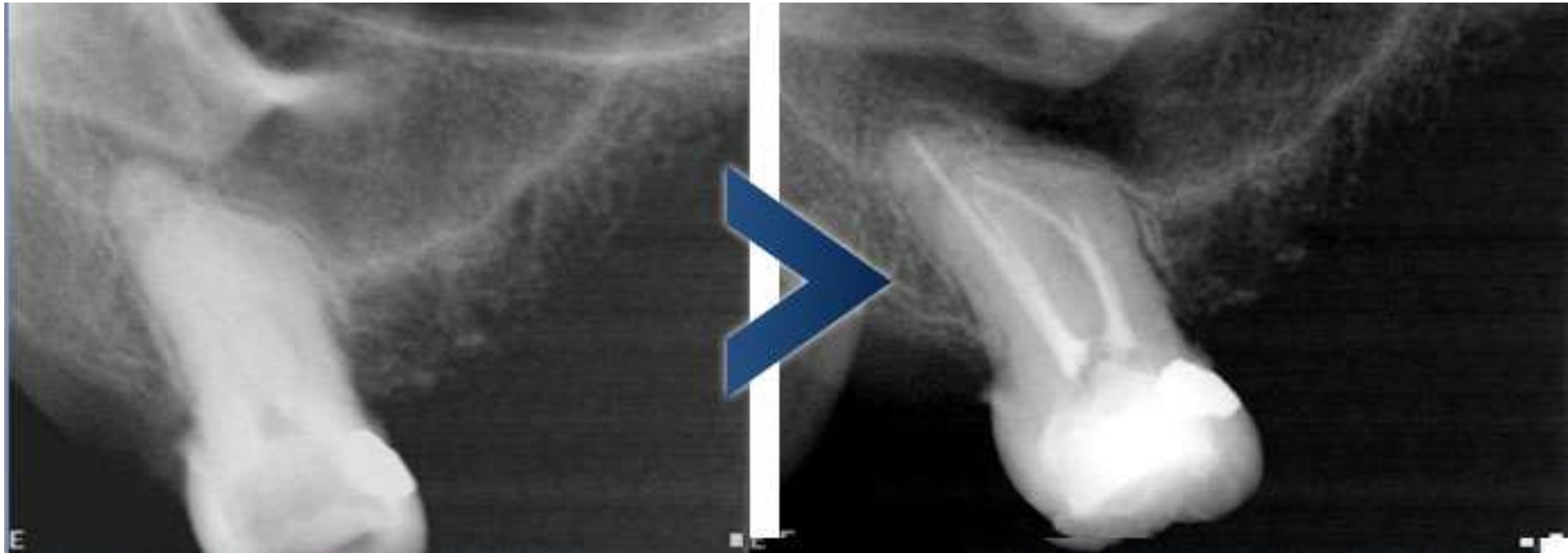
Female patient - age: 49

- * Tooth 3.6 with three canals
- * Distance from top to bottom of pulpar chamber extremely small
- * Irreversible painful pulpitis



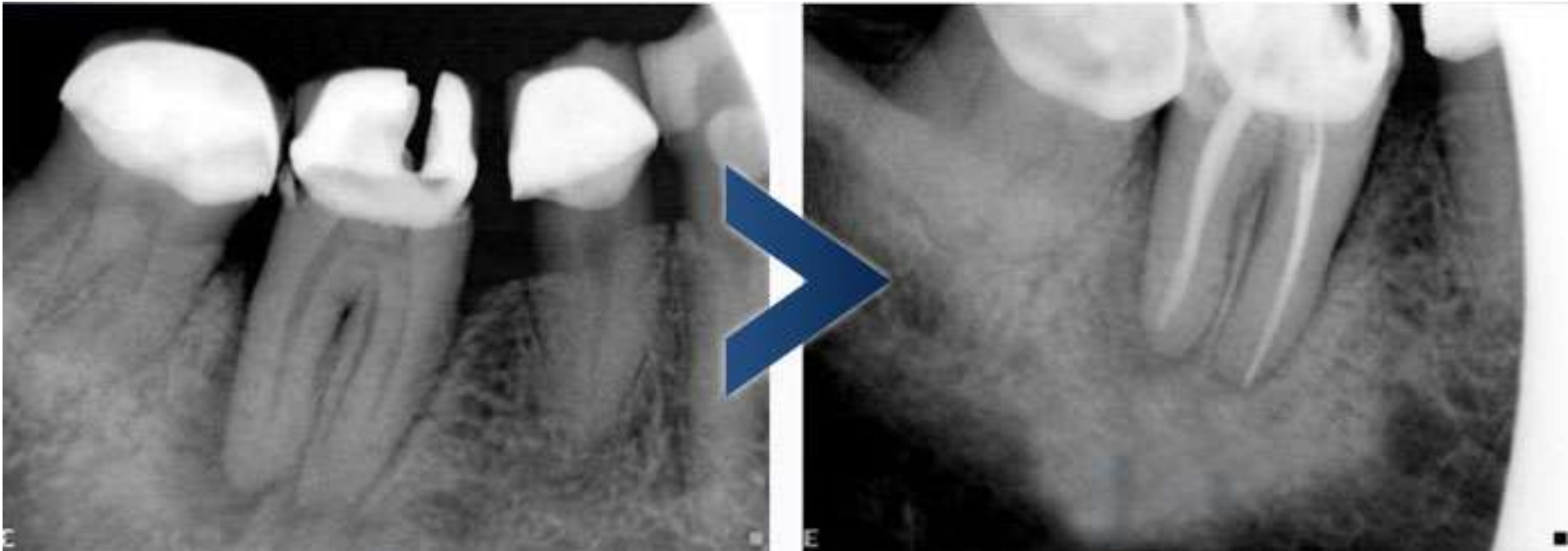Female patient - age: 65

- * Tooth 1.7 with four canals
- * Irreversible painful pulpitis
- * Intense vomit reflex, required pre-medication



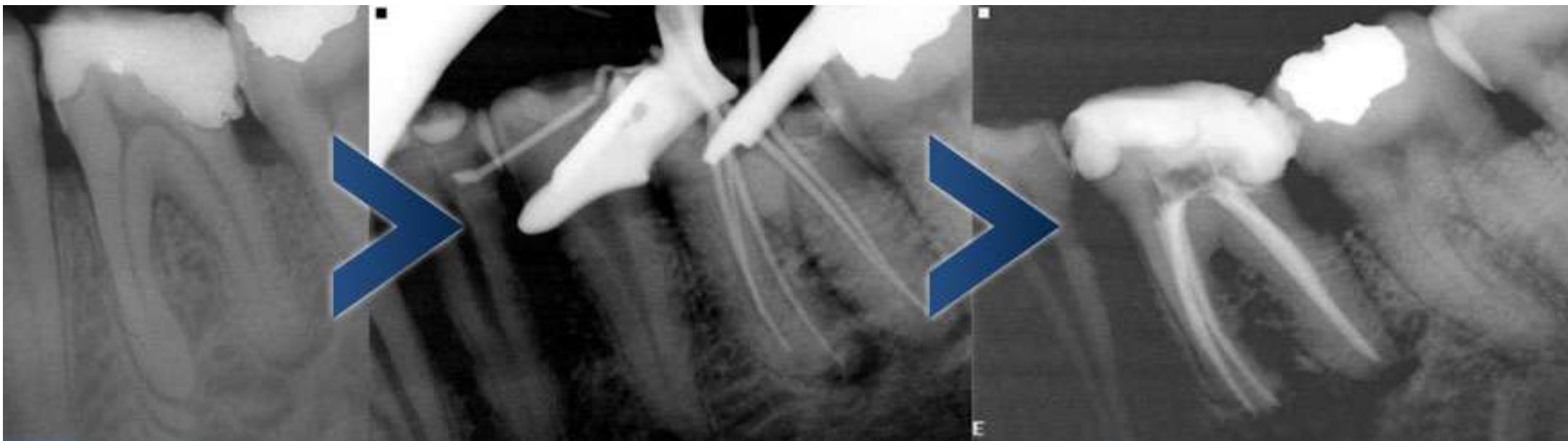
Female patient - age: 72

- *Tooth 4.6 with two canals
- *Chronic periapical periodontitis
- *Endo-perio lesions
- *Porcelain crown
- *Distance from top to bottom of pulpar chamber extremely small



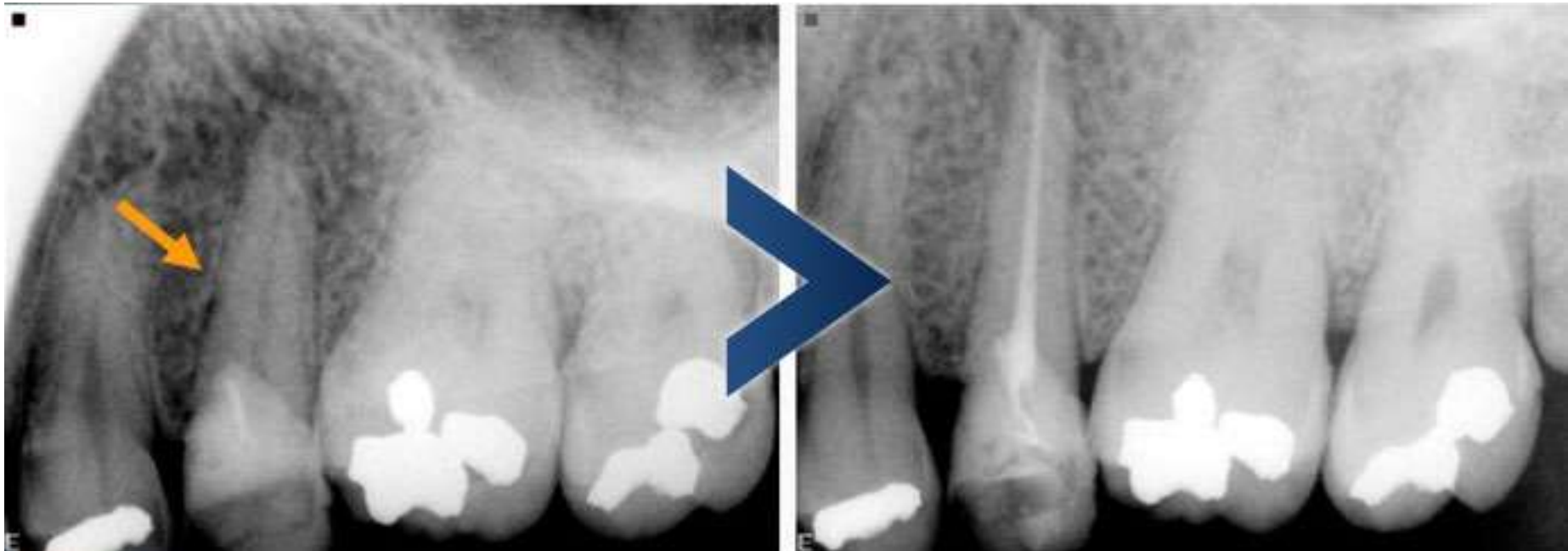Male patient - age: 36

- * Tooth 3.6 with FIVE canals
- * Acute periapical abscess
- * Required prostodontic evaluation



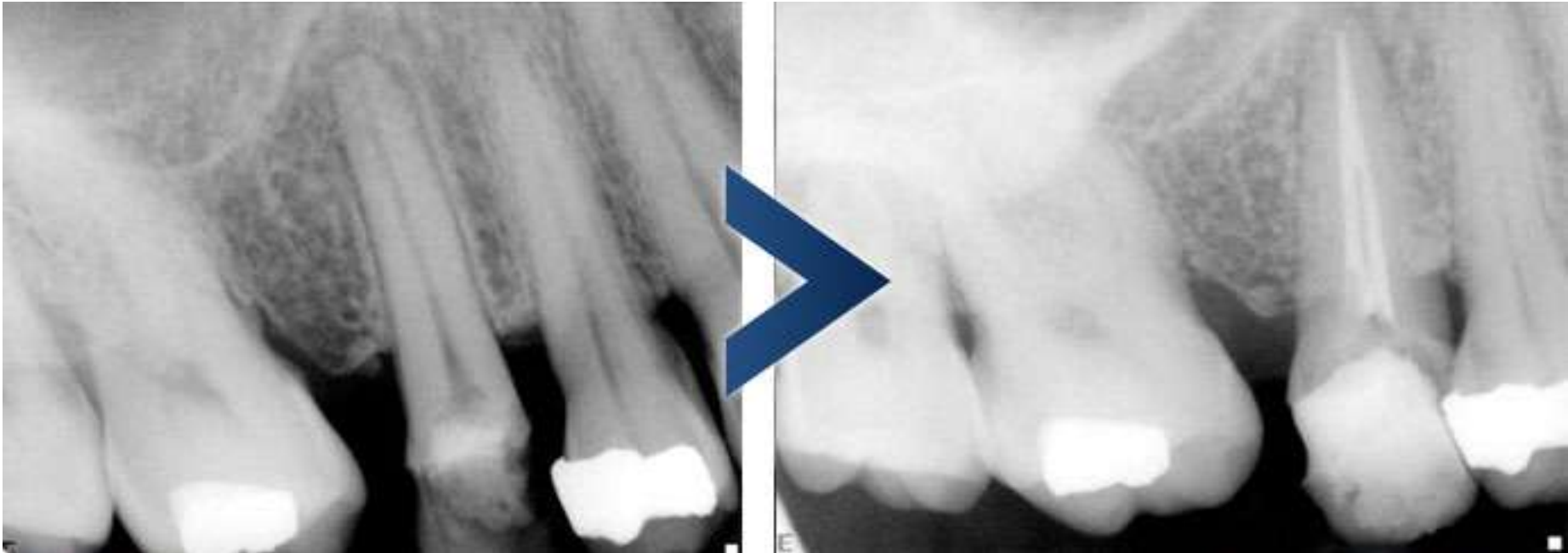
Male patient - age: 50

- * Tooth 2.5 with one canal
- * Acute periapical abscess
- * Possible root fracture due to dental mobility
- * Previous resin+ pin restoration



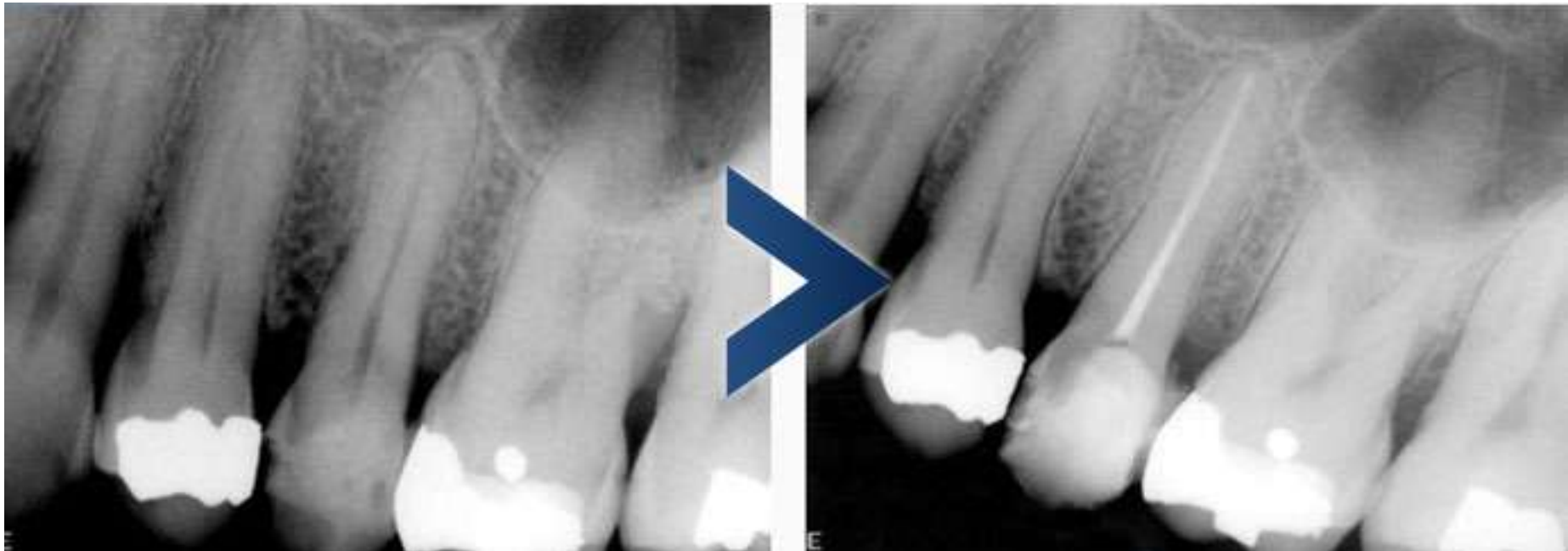Male patient - age: 56

- * Tooth 1.5 with two canals
- * Unfinished previous canal treatment



Male patient - age: 56

- * Tooth 2.5 with one canal
- * Irreversible painful pulpitis
- * Fracture of palatine cuspid



Male patient - age: 56

- * Tooth 2.6 with three canals
- * Irreversible painful pulpitis
- * Deep caries

